

# Geriatric Otolaryngology



Ravi Pachigolla, MD  
Byron Bailey, MD

# Introduction



- Multiple diseases coexist in patients
- Elderly suffer from a unique set of illnesses
- Unusual symptoms common without symptoms such as pain and fever
- Otolaryngologists play vital role in prevention of illness

# Biology of Aging



- Wounds heal slower
- Retarded fibroplasia
- Collagen decreases with age
- Elastic fibers decrease with age
- Functional capacity of cells are decreased
- Decreased ability of older patients to remodel collagen laid down

# Medical and Surgical treatment in the elderly



- Adverse side effects from medications common
- Sensitivity to drugs increases with age
- Renal clearance and hepatic metabolism both decrease with age
- Evaluate drug - drug interactions before beginning new treatments
- Perform surgical procedures in the elderly with caution

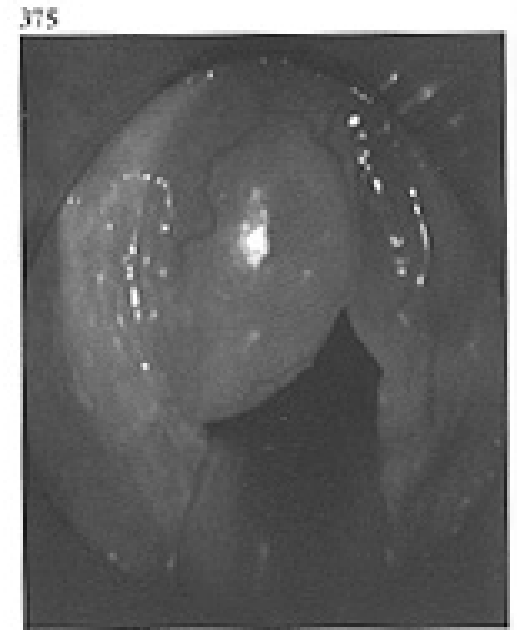
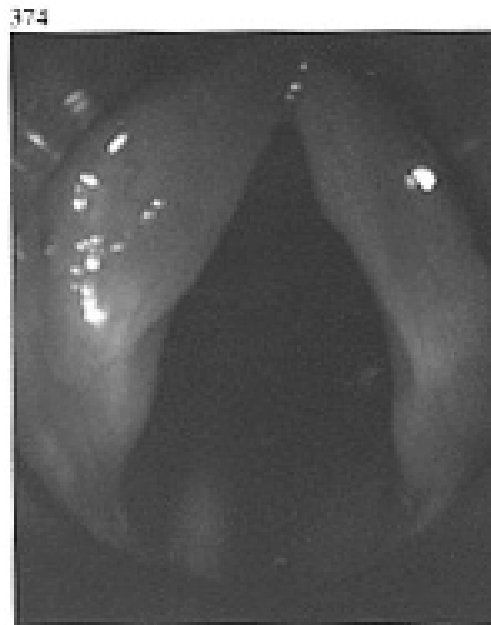
# Geriatric Voice



- 10 to 15 percent of elderly have some dysphonia
- Dysfunctions may be age related or related to disease processes
- Characteristics of the aging voice

# Geriatric voice continued

- Laryngoscopy shows discoloration, bowing, atrophy and occasionally edema
- Jitter (cycle to cycle frequency variation) increases with age
- Increased fundamental frequency in men
- Decreased fundamental frequency in women

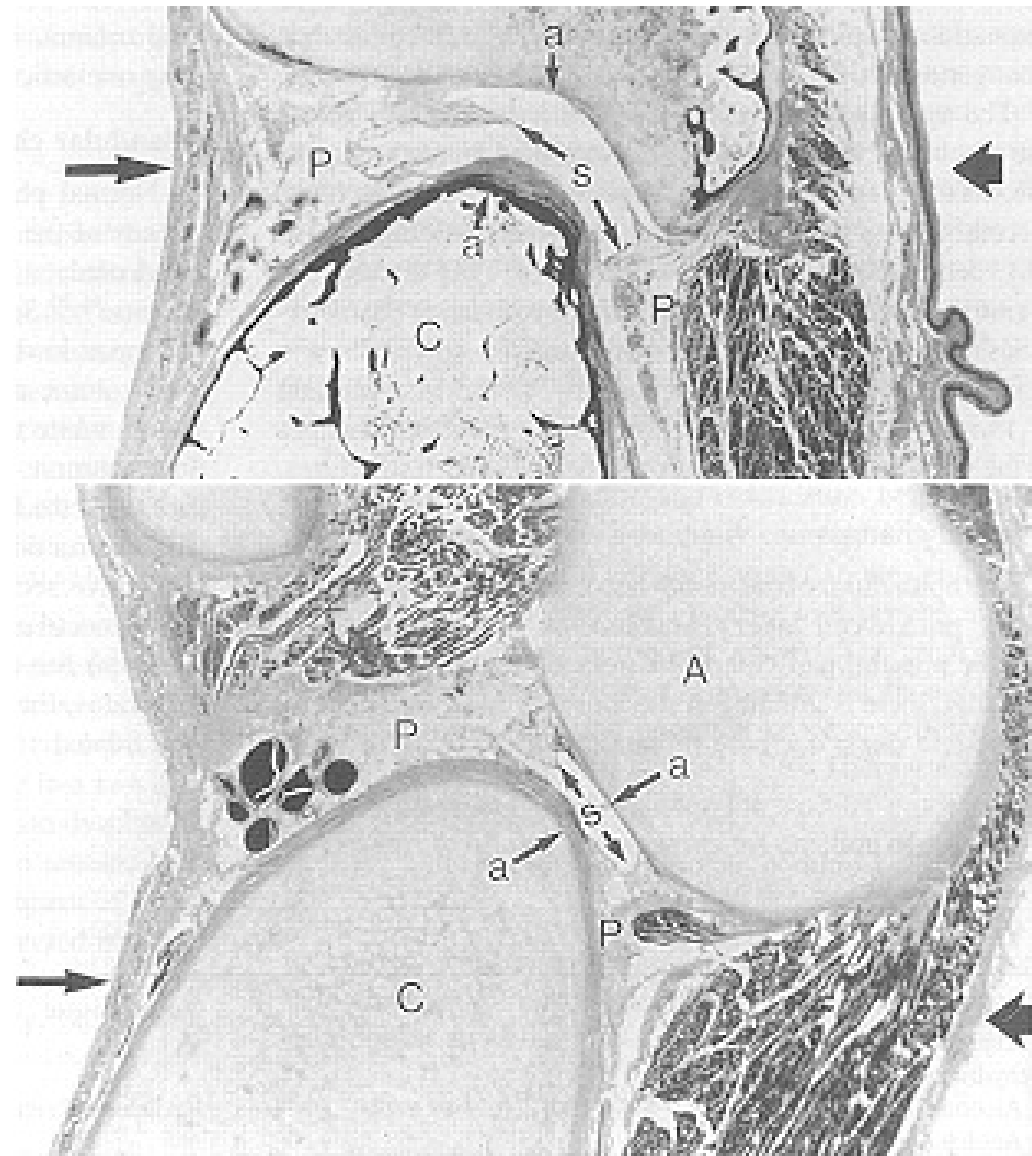


# Structural vocal fold changes



- Decreased amounts of collagen fibers
- Vocal ligament fibrosis
- Vocal fold atrophy with glottal gap
- Laryngeal muscle atrophy with increased amounts of connective tissue and fatty infiltration
- Age related degenerative changes
- Poor mucosal hygiene

Fig. 15-1. A, Young cricoarytenoid joint (patient is 29 years of age). A—Arytenoid, C—Cricoid, a—Articular surface, S—Synovium, P—Periarticular soft tissues, Hypopharyngeal epithelium (*fat arrow*), Subglottic respiratory epithelium (*thin arrow*). (Hematoxylin-eosin;  $\times 3$ .) B, Old cricoarytenoid joint (patient is 69 years of age). A—Arytenoid, C—Cricoid, a—Articular surface, S—Synovium, P—Periarticular soft tissues, hypopharyngeal epithelium (*fat arrow*), subglottic respiratory epithelium (*thin arrow*). Note increased calcification and muscle atrophy. (Hematoxylin-eosin;  $\times 3$ .)



# Pathologies affecting the vocal folds



- Essential tremor - can lead to ventricular dysphonia
- Parkinson's - low, breathy, monotonic voice
- Be aware of the benign and malignant lesions affecting the vocal folds

# Medical treatment of vocal fold disorders

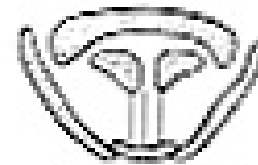
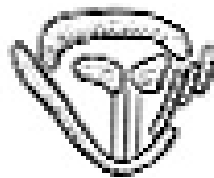
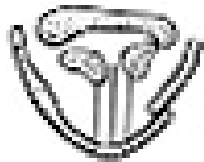
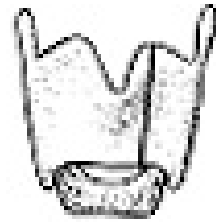


- Avoidance of compensatory maneuvers
- Women strain to increase vocal pitch which can result in hyperadduction of the false vocal folds
- Men may attempt to lower pitch resulting in a gravelly, breathy voice that is easily fatigued
- Thus prevention of compensatory functional misuse is important
- Speech therapy - men may gradually adjust their vocal pitch upwards, women attempt to relax their laryngeal muscles

# Surgical treatment of vocal fold disorders




- Isshiki type 4 thyroplasty
- Gelfoam or lipoinjection
- Anterior commissure laryngoplasty
- Surgery remains a last resort if all other options have been exhausted



Type II : Lateral Expansion

Type IV : Lengthening



Cricothyroid  
Approximation

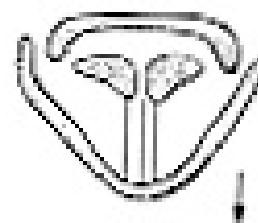
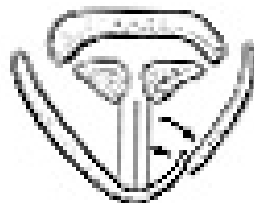
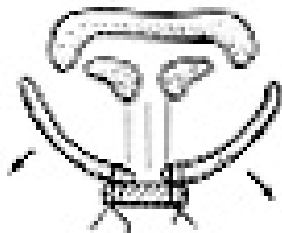


Fig. 3. Four types of thyroplasty.

# Effects of aging on swallowing




- Age related changes noted in the oral, pharyngeal and esophageal phases of swallowing
- Increased fatty and connective tissue in the tongue
- Atrophy of the alveolar bone and reduced chewing capabilities
- Transit times increased through pharynx and esophagus
- Most of these changes are academic because these changes do not generally increase the incidence of dysphagia, laryngeal penetration or aspiration

# Age related disease processes affecting swallowing



- Left sided cva's lead to difficulties during the oral phase of swallowing
- Right sided cva's lead to difficulties with the pharyngeal phase of swallowing
- Motor neuron disease
- Parkinson's has a typical pattern of repetitive tongue movements, delayed pharyngeal swallow and pharyngeal residue
- General medical conditions include rheumatoid arthritis, diabetes, and polymyositis
- Modified barium swallow crucial in providing information
- Dysphagia may be related to cricopharyngeal achalasia- an unexplained failure of the ues to relax in a coordinated manner

# Treatment of swallowing disorders



- Treatment is multidisciplinary
- Often rehabilitation is all that is needed to improve swallowing
- Voluntary maneuvers include the supraglottic swallow or mendelsohn maneuver
- In those patients who are unable to comply with voluntary instructions, postural techniques, volume changes or changes in food or diet consistency is all that is needed to improve swallowing
- CPM may be used in those patients with isolated cricopharyngeal achalasia

# External and middle ear changes

- Actinic problems common
- Decreased cerumen production
- Longer tragi hairs contribute to decreased cerumen migration
- Middle ear histologic change noted but no hearing loss usually results from these changes

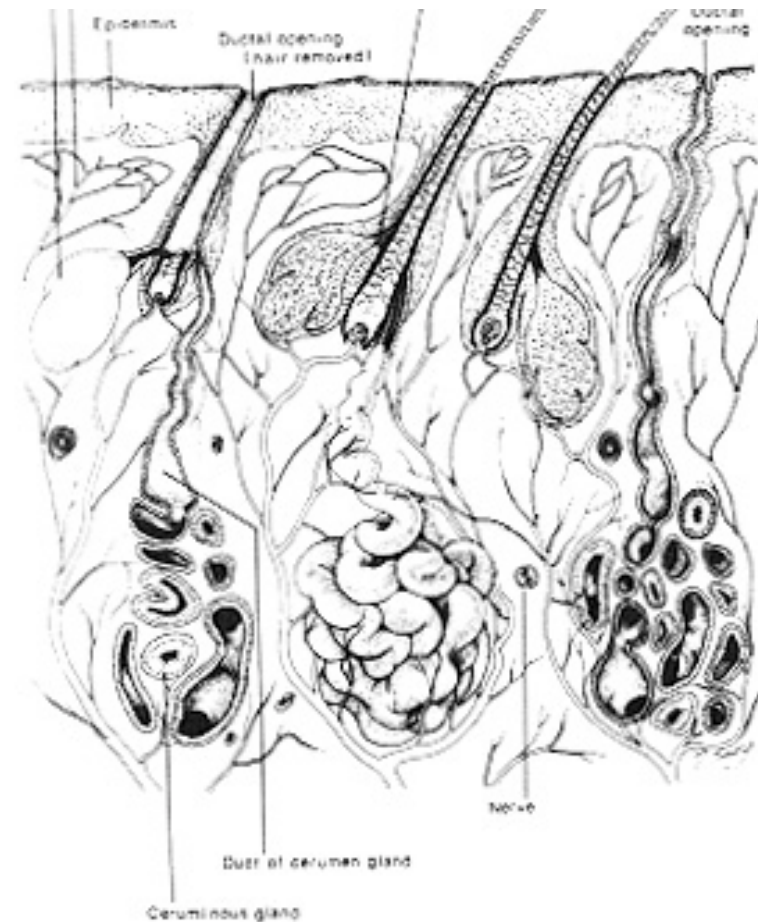

Figure 1. Drawing of skin of lateral portion of external auditory canal. (From Main, T., and Lim, D. The human external auditory canal secretory system—an ultrastructural study. *Laryngoscope*, 86:1164-1176, 1976.)

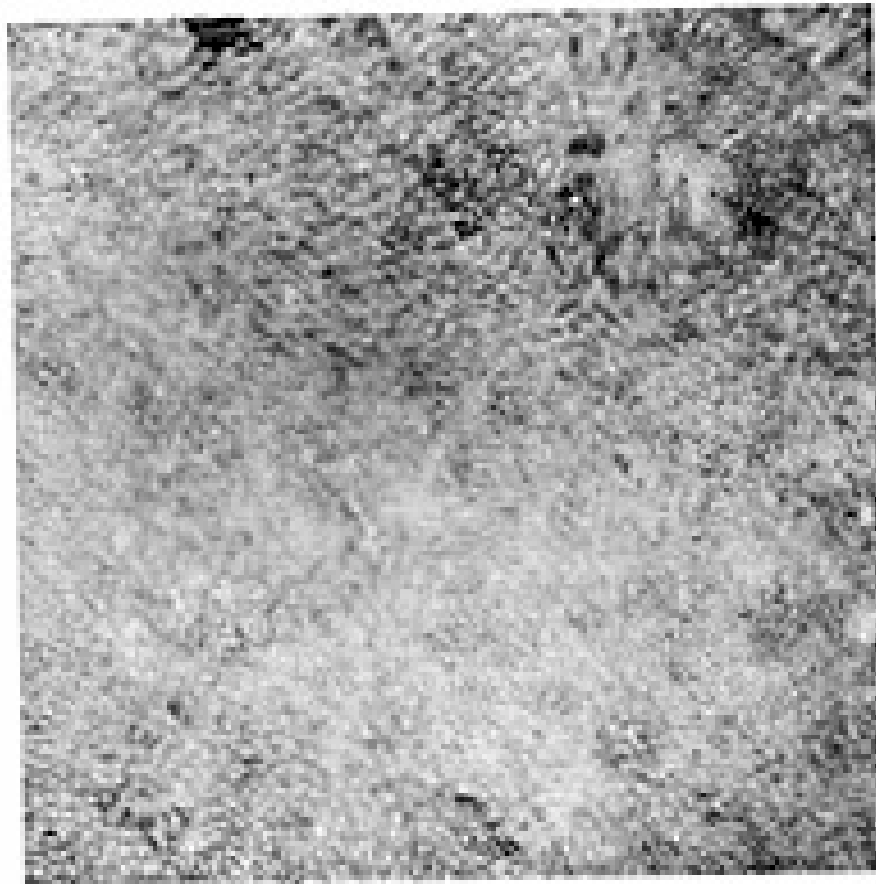


Figure 4 Actinic keratoses of the cheeks. Hundreds of keratoses are present with individual lesions varying in size from 2 to 10 mm. The appearance is that of gray scales loosely adherent to the underlying sun damaged skin

# Presbycusis



- Age related decline in auditory function
- Noise induced hearing loss is complementary
- Outer and inner hair cells lost from the basal turn of the cochlea
- Speech discrimination is affected commonly
- Older patients required an increased interaural time delay to discern high frequency sounds
- This affects their ability to understand speech in social settings

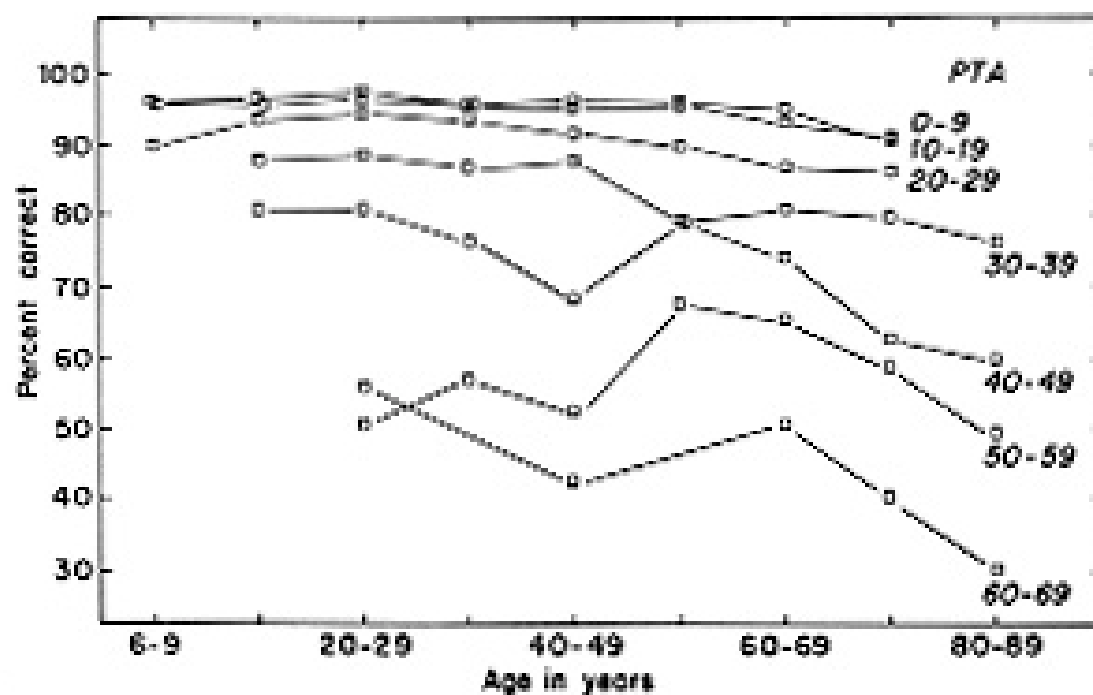


Figure 7. For a given pure tone hearing loss the percentage of correct responses for speech discrimination decreases with increasing age. (From Jerger, J.: Audiological findings in aging. *Adv. Otorhinolaryngol.*, 20:115-124, 1973. Reprinted by permission of S. Karger AG, Basel.)

# Sensory Presbycusis



- Bilateral abruptly sloping high frequency sensorineural hearing loss
- Speech discrimination good
- Degeneration noted near the basal portion of the organ of corti

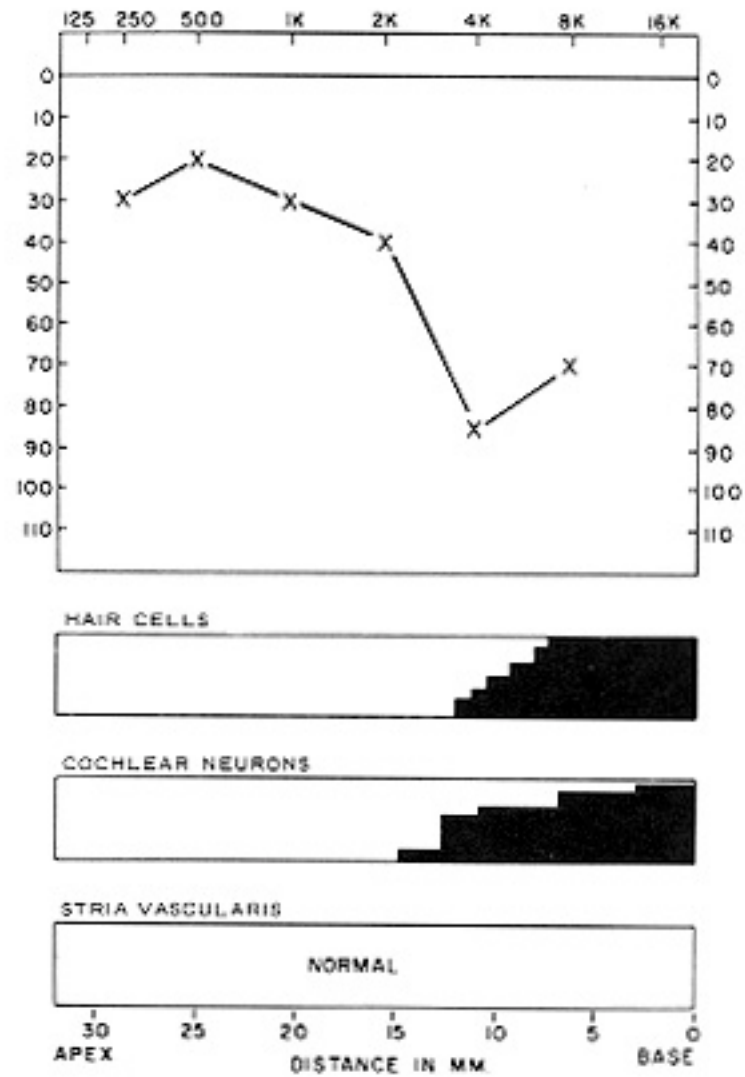


Figure 3. Sensory presbycusis in 79 year old male. Abrupt high tone hearing loss with atrophy of hair cells (organ of Corti) and cochlear neurons in basal end of cochlea. (Reprinted by permission from Schuknecht, H.: *Pathology of the Ear*. Cambridge, Harvard University Press, 1974, p. 390.)

# Neural Presbycusis



- Rapid hearing loss
- Difficulties with speech discrimination
- Pure tone reveals a moderate to a flat tone loss
- Loss of spiral ganglion cells

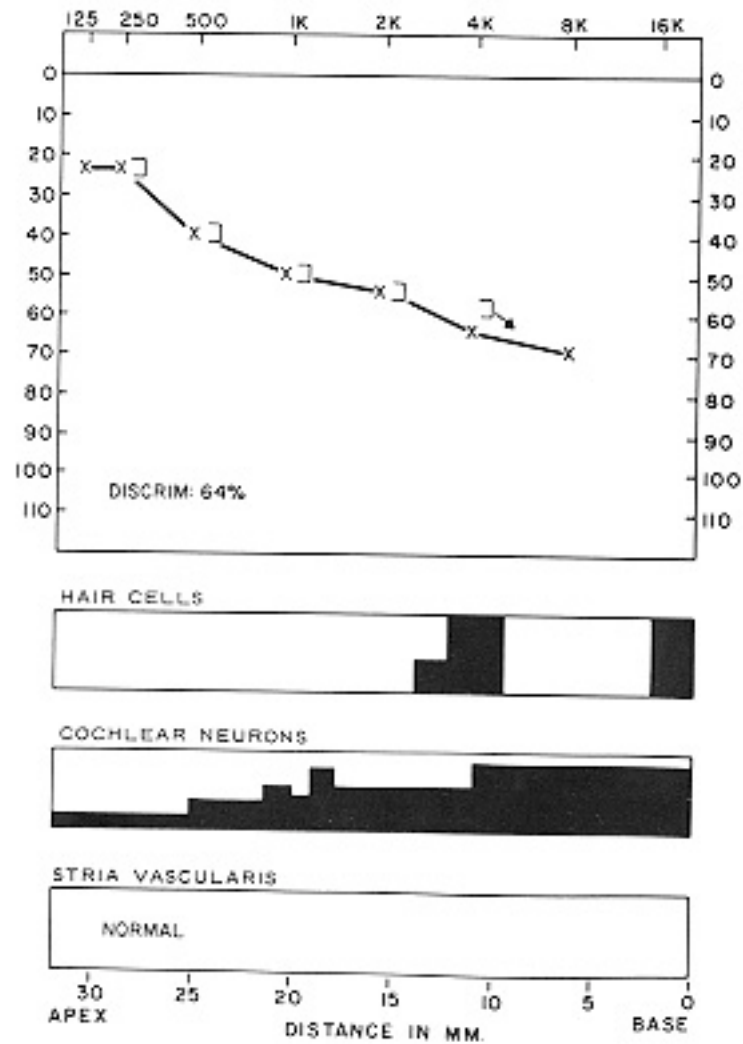


Figure 4. Neural presbycusis in 81 year old male (possibly with some associated sensory presbycusis). Note small areas of hair cell loss in basal end of cochlea and severe diffuse loss of cochlear neurons, most severe in basal turn of cochlea. (Reprinted by permission from Schuknecht, H.: Pathology of the Ear. Cambridge, Harvard University Press, 1974, p. 393.)

# Metabolic Presbycusis



- Slowly progressive sensorineural hearing loss
- Flat loss with good discrimination
- Atrophy of the stria vascularis may be noted

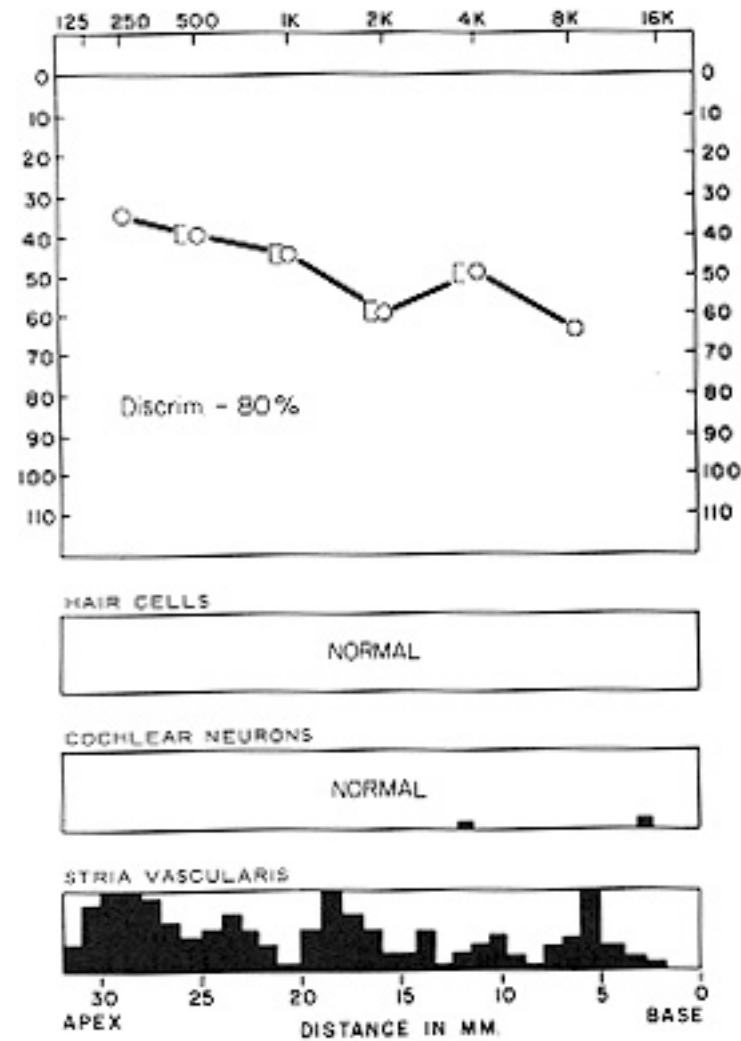


Figure 5. Strial presbycusis in 72 year old female. Note the normal organ of Corti (hair cells) and cochlear neurons. There is severe patchy atrophy of the stria vascularis throughout the cochlea. (Reprinted by permission from Schuknecht, H.; Pathology of the Ear. Cambridge, Harvard University Press, 1974, p. 396.)

# Cochlear or conductive presbycusis



- Thickened basilar membrane
- No hair cell loss
- Good speech discrimination with gradual sloping high tone loss

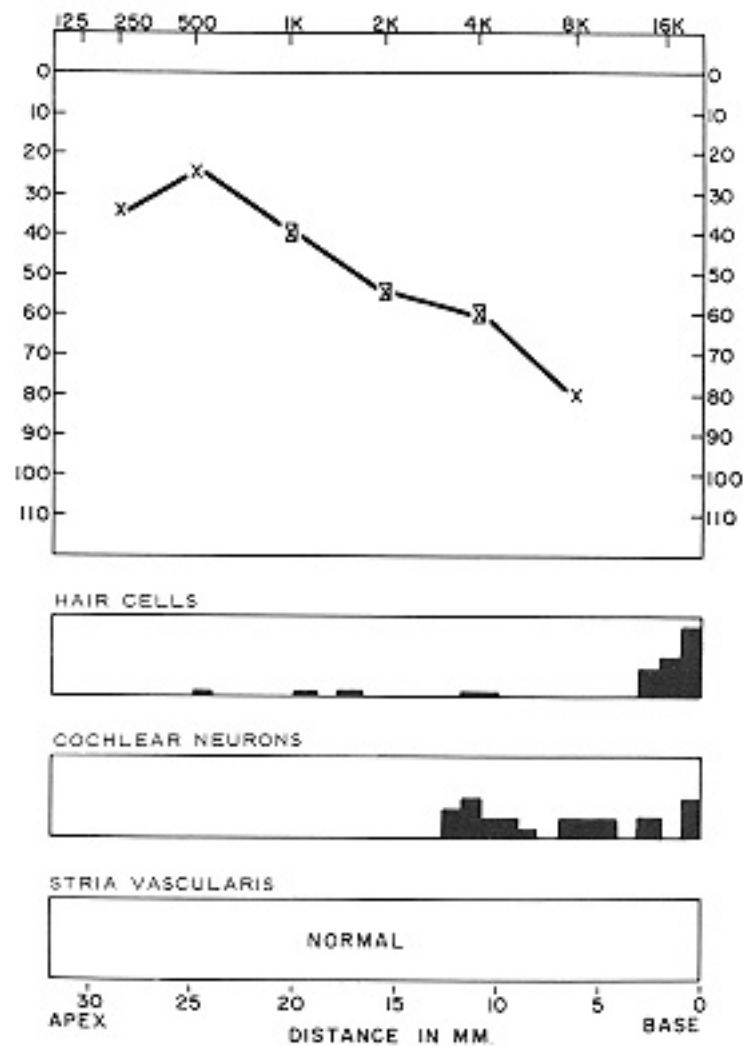


Figure 6. Cochlear conductive presbycusis in 88 year old male (speech discrimination 72 per cent). Note minimal hair cell and neuronal loss in the basal end of the cochlea, neither of which is adequate to explain the degree of hearing loss. (Reprinted by permission from Schuknecht, H.: Pathology of the Ear. Cambridge, Harvard University Press, 1974, p. 400.)

# Presbyastasis



- Dysequilibrium of aging
- Diagnosis of exclusion
- Sense of imbalance common
- Risk of falling significant
- Increased body sway common
- Reduced hair cells in the crista and macula
- Generalized peripheral hypofunction of the labyrinth common which can lead to imbalance

# Treatment of presbyastasis



- Balance disorders involve the vestibular, proprioceptive, visual and central nervous system
- Deficits can be partially compensated by the other systems
- Nonvestibular causes of presbyastasis such as postural hypotension need to be identified and treated specifically
- Vestibular habituation involves repeated elicitation of minor degrees of vertigo
- Other maneuvers involve visual tracking with the head held stationary and also gaze stability with head movement
- Vestibular suppressants should be avoided

# Aging Face



- Atrophy of the subcutaneous fat
- Slow degeneration of the skin's elastic and collagen network
- Gradual resorption of the facial skeleton
- Descent of brows and glabellar tissues below the bony supraorbital rims
- Correction involves standard or endoscopic browlifts and midface procedures with implants or rhytidectomy

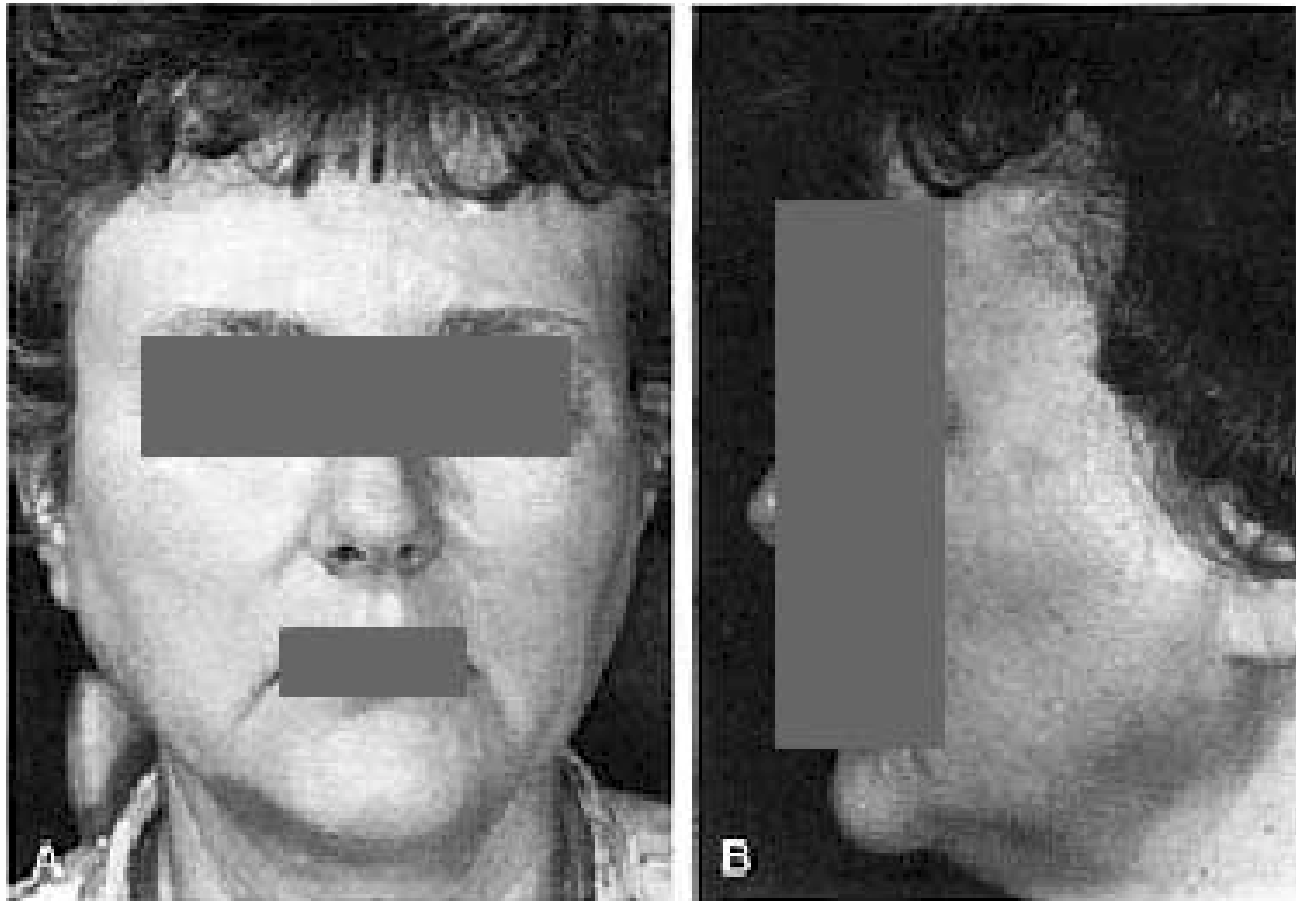

Figure 1.A and B. Typical changes that result from the long-term effect of gravity on the face. Ptosis of the forehead, brows, cheeks, jowls, chin, and neck are clearly present. Marked dermatochalasis of the upper eyelids accentuates the appearance of advanced age.

# Aging Nose



- Tip ptosis
- Weakness of the tip support mechanisms
- Inferior and posterior repositioning of the nasal tip
- Techniques to correct this include a “nose lift”
- This may involve resection of the cephalic border of the lower lateral crura and/or strut placement between the medial crura which allows the medial crura to be positioned more anteriorly

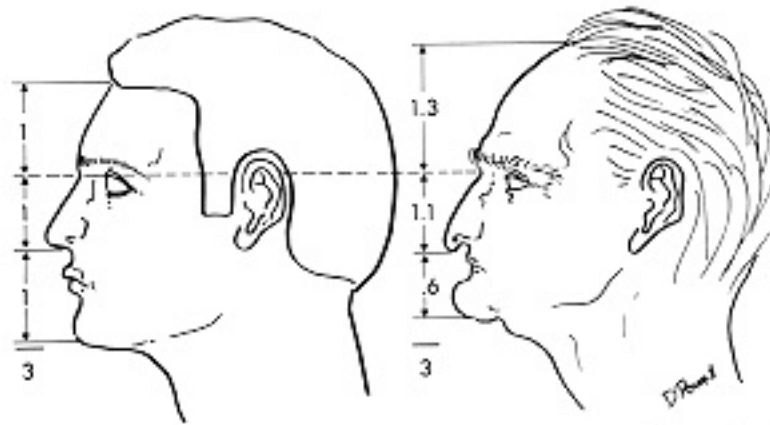


Figure 2. Note the changes in the proportions of the three vertical dimensions of the face. The nose is actually longer and looks relatively longer.

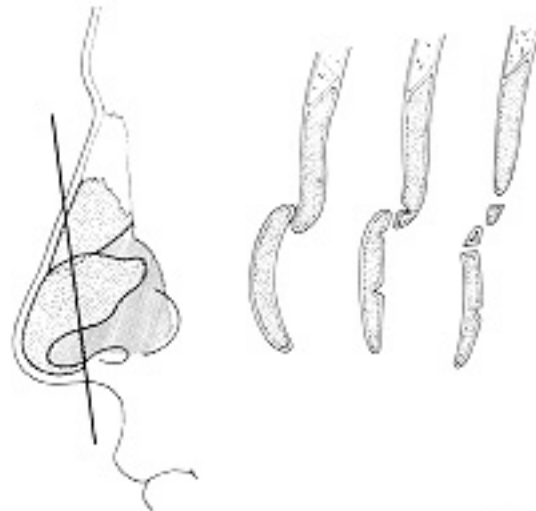


Figure 3. Note separation and, finally, fragmentation of the cartilage. (From Krmpotić-Nemanić, J., Kostović, I., and Rudan, P.: Aging changes of the form and infrastructure of the external nose. *Plast. Reconstr. Surg. Face Neck*, 1:8, 1970. By permission.)

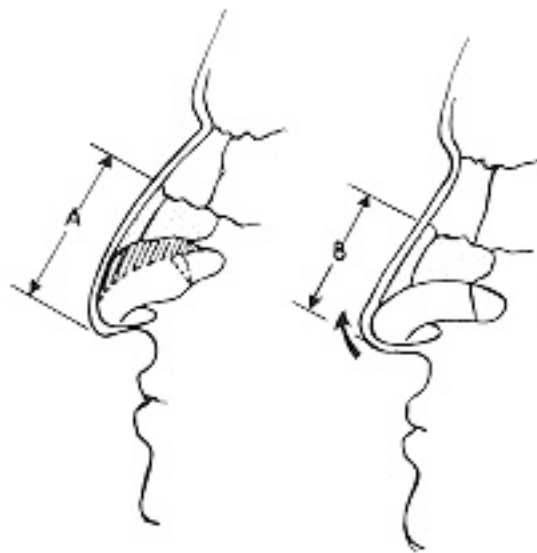


Figure 9. Shortening of the nose often obliterates the hump and makes the upper lip appear longer.

# Facial fractures and aging



- Resorption of mandibular and maxillary alveolar bone
- Total mandibular height may be reduced up to 50% in edentulous patients
- Techniques used in repair are less invasive, require less dissection and introduce less hardware into the wound
- Healing is prolonged
- TMJ often affected in aging

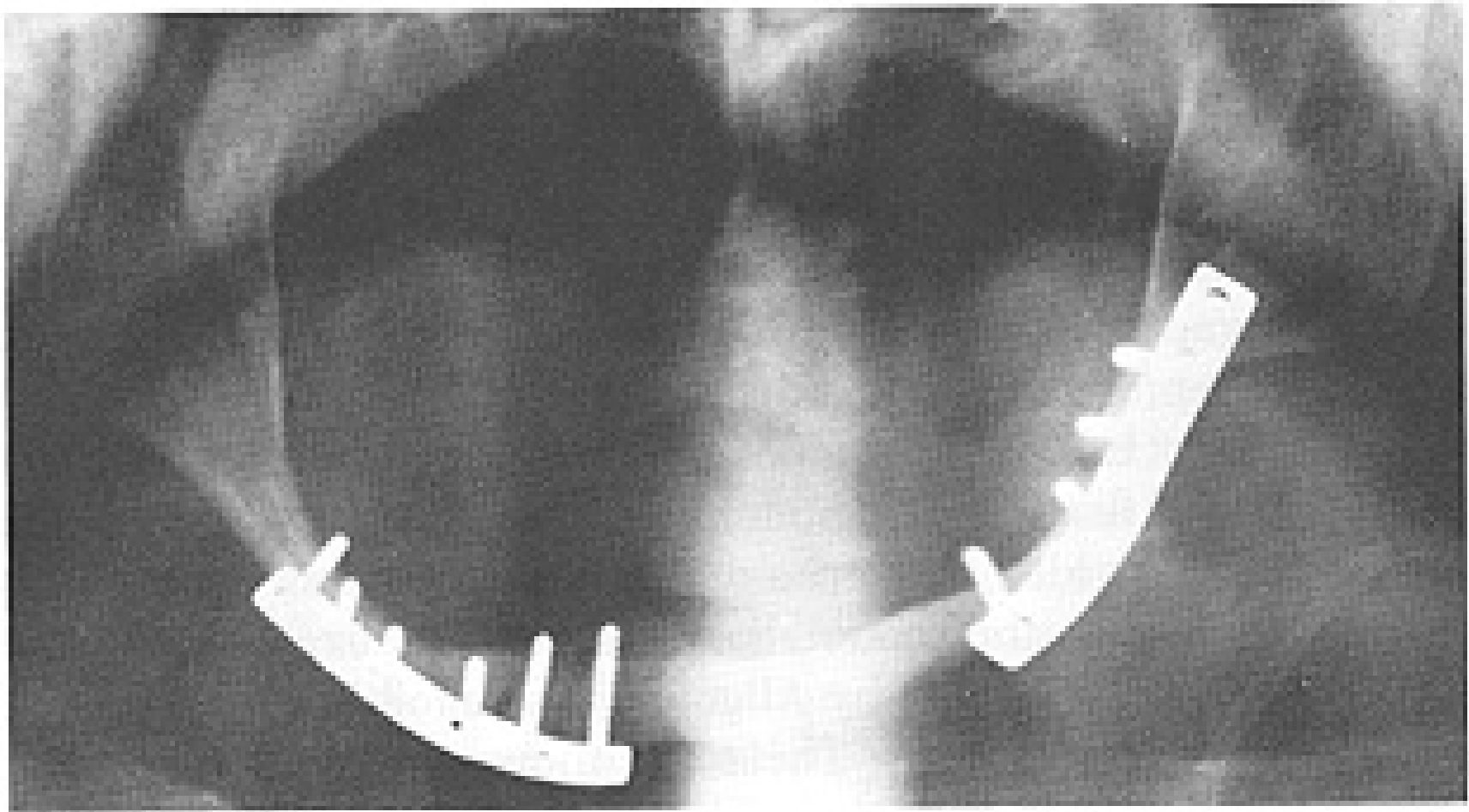


Figure 3. Management of bilateral mandibular fractures with dynamic compression plating. (From Spiessl B: *Internal Fixation of the Mandible*. New York, Springer-Verlag, 1989; with permission.)

# Aging and pulmonary function

- Decreased vital capacity, pulmonary compliance and elastic recoil noted
- Body weight increases
- Phonation affected by this decreased vital capacity
- Decreased ability to maintain pitch, loudness and airflow

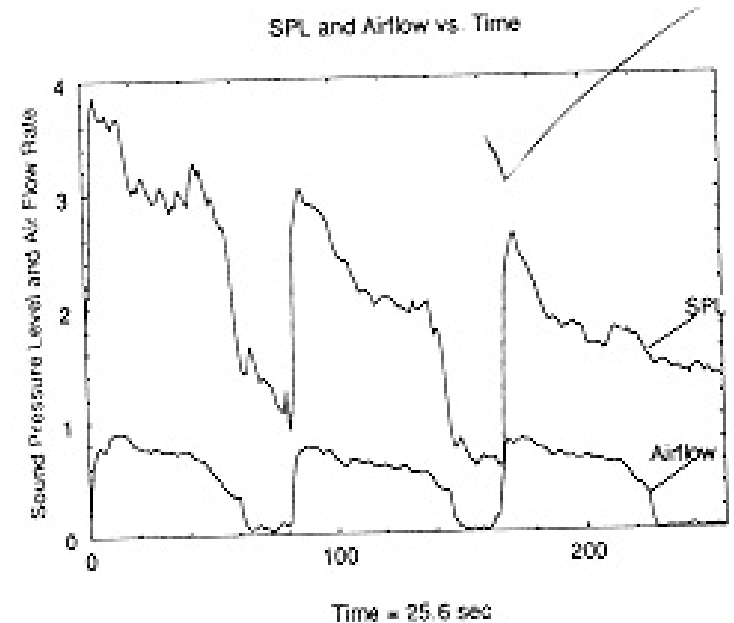


Fig. 2. Simultaneous measurement of mean phonatory airflow and sound pressure output during sustained phonation of modal /ae/ from a 73-year-old man with breathy, weak voice due to aging. X axis = 25.6 seconds. Y axis: top tracing is sound pressure output, bottom tracing is airflow. Note the short sustained phonation time, the variability in sustained sound pressure output, and the slope of the airflow and acoustic output through the phonation cycle. Three cycles of phonation are plotted.


# Aging and the paranasal sinuses



- Nasal ciliary epithelium generally not altered by age or smoking
- Effect of age on mucociliary transport is modest
- Loss of nasal structural support can increase nasal obstruction
- Nasal complaints common
- Avoidance of decongestants, diuretics and antihypertensives which may dessicate the nose

# Olfaction

- Olfactory neuroepithelium replaced by respiratory epithelium with age
- Degenerative diseases, viral infections, endocrine disorders and trauma also play a role in decreased olfaction
- Basis for changes in age related olfaction still not entirely clear and is clouded by other factors in these patients



# Head and Neck Oncology



- More than one half of all cancer patients are older than 65
- Many elderly patients with proper preop counseling and preparation can tolerate head and neck cancer surgery well - as few as two weeks of preop preparation may be all that is needed to get patients ready for surgery
- Speech and swallowing rehabilitation delayed
- Most common nonsquamous tumors are thyroid and parotid malignancies
- Anaplastic thyroid carcinoma is much more common in patients over 65
- Medullary and thyroid lymphomas are also commonly seen
- Even well differentiated thyroid cancer behaves more aggressively
- Parotid neoplasms tend to be higher grade neoplasms especially mucoepidermoid carcinoma